

Pulmonary Manifestations of Dengue: Case Series

Pooja Das¹, Mahendran.C.S^{2*}, Prachi Saxena³, Sanjay Sahay⁴,
Eshutosh Chandra⁵, Sarath Sivaji⁶

¹MBBS, Postgraduate, Department of Respiratory Medicine, Santosh Hospital

²DTCD, DNB, FCCP, Assistant Professor, Department of Respiratory Medicine, Santosh Hospital

³DNB, Assistant Professor, Department of Respiratory Medicine, Santosh Hospital

⁴MD, DIH, Professor and HOD, Department of Respiratory Medicine, Santosh Hospital

^{5,6}MBBS, Post Graduate, Department of Respiratory Medicine, Santosh Hospital

Corresponding Author: Dr. Mahendran.C.S

Date of Submission: 10-12-2021

Revised: 20-12-2021

Date of Acceptance: 25-12-2021

ABSTRACT

Rationale: Dengue is an arthropod-borne viral infection transmitted to humans through bites of infected female Aedes mosquitoes. Pulmonary manifestations are rare can present as pleural effusion, pneumonia, non-cardiogenic pulmonary edema, acute respiratory distress syndrome which coincides with decreased platelet count and capillary leakage.

Patient concern: pleural effusion, pneumonia, pneumothorax

Intervention: fluids, antibiotics, analgesics and antipyretics, intercostal drainagetube.

Conclusion: Pulmonary manifestations in dengue fever are rare. Dengue fever can be considered as a differential diagnosis in patients with pleural effusion and pulmonary infiltrates if recognized early and intervened to prevent mortality.

Keywords: Dengue, Pleuraleffusion, Pneumonia.

I. INTRODUCTION

Dengue is an arthropod-borne viral disease transmitted by infected female Aedes mosquito bites. NS1 is an acute-phase antigen obtained within five days of the onset of fever. IgM becomes positive after day 5. Pulmonary manifestations are rare which include pleural effusion, pneumonitis, acute respiratory distress

syndrome, pulmonary hemorrhage[1]. Dengue hemorrhagic fever has a course with persistent fall in platelet count and leakage of plasma[3]. Dengue viral antigens are found in autopsy specimens. It affects the epithelial and endothelial cells of the lungs[4]. Staphylococcal pneumonia is oftenseen in dengue patients. Exacerbation of pneumonia can be attributed to co-infection between dengue and influenza[6].

CASE 1

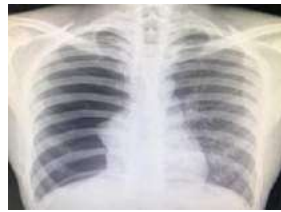21-year old male, presented to the outpatient department with high grade, continuous fever for 3 days, shortness of breath, and sudden onset of chest pain for one day. Shortness of breath was grade 2 mMRC for one day associated with sudden onset of chest pain on the right side which was stabbing and catchy in nature, non-radiating, and not relieved with medications.

No history of other respiratory symptoms or ailments in past. History of constipation on and off since one year.

Not a known smoker or alcoholic.

Systemic examination of Respiratory System:

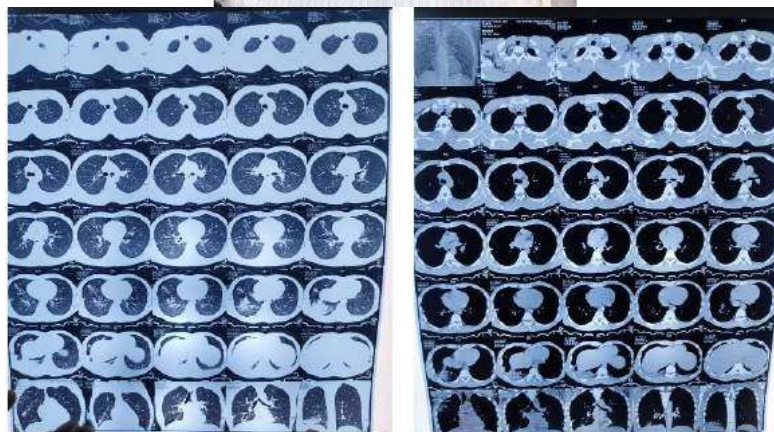
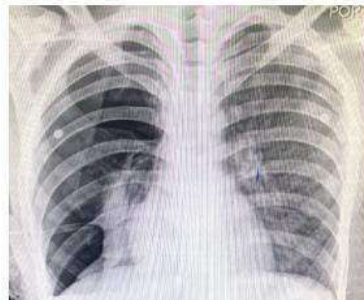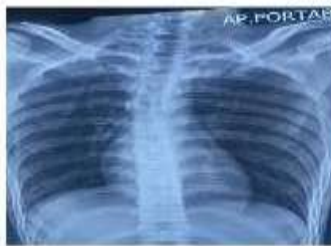Intercostal space fullness, reduced respiratory movements with hyper resonant percussion note, absent breath sounds on the right side. Urgent x-ray showed a hyperlucent area on the right side with collapsed lung suggestive of pneumothorax



The patient was treated with antibiotics, antipyretics, analgesics and intercostal drain inserted in the right fourth intercostal space in mid axillary line ,attached to an underwater seal. The patient's complete blood count picture showed leukopenia and thrombocytopenia with a total

leucocyte count of 2900 and platelet count of 99000,positive fordengue NS1 antigen and IgM antibodies .

The patient was monitored with serial platelet counts along with chest x ray.



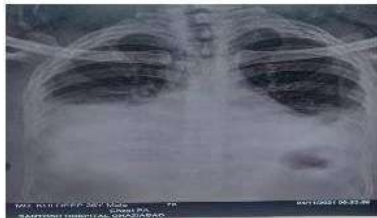Subsequent chest X-rays showed gradual expansion of the lung with the resolution of pneumothorax.

The patient underwent a high-resolution CT scan of the thorax on day 4 which showed right lower lobe patchy consolidation and partial resolution of

pneumothorax with intercostal drain insitu.

CASE 2

A patient aged 30 years presented to the emergency with fever for five days which was continuous high



The patient also had complaints of shortness of breath for three days grade 2mMRC not associated with wheezing, cough with expectoration. History of chest pain on deep inspiration was present.

No history of other co-morbidities, smoking or allergies.

At the time of presentation, the patient had a saturation of 82 percent oxygen with room air which improved to 96 percent with oxygen therapy.

The patient had a total leucocyte count of 2250 with a platelet count of 15000, dengue NS1 and IgM positive and was managed with antibiotics, analgesics and diuretics.

Chest x-ray showed bilateral massive pleural effusion which resolved in subsequent chest x-rays following diuretic therapy.

5 days later platelets improved to 95630 with a total leucocyte count of 5243.

CASE 3

Patient aged 27 years old male presented to the emergency with complaints of shortness of breath grade 3 mMRC for one week associated with wheezing and allergic rhinosinusitis.

He had cough with scanty, white-colored sputum, mucoid inconsistency for three days, complaints of high grade, intermittent fever for three days which was relieved with medications.

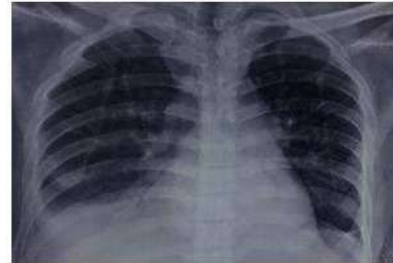No history of chest pain, hemoptysis, loss of appetite, and loss of weight.

No history of smoking, biomass exposure, environmental exposure.

No history of ATT intake.

At the time of presentation, the patient was tachypneic with a respiratory rate of 30/min and was having a saturation of 85 percent with room air which improved to 95 percent with oxygen therapy via face mask. The patient was tachycardic with a heart rate of 115/min and

grade in nature associated with chills, rigors, and body pain.



temperature 102 degrees F.

On examination of the respiratory system, the patient was tachypneic with increased vocal fremitus on the right suprascapular and infraclavicular areas and in the left infrascapular area.

On auscultation, tubular bronchial breathing present in the right suprascapular and infraclavicular areas with bilateral fine crepitations and polyphonic wheeze.

The patient had a low platelet count of 86000 with a total leucocyte count of 3246 on day of admission and positive for dengue NS1 antigen

Chest x-ray showed a homogenous patch on the right upper zone and left lower zone. The patient was initiated on IV fluids, antibiotics, analgesics, inhaled bronchodilators and oxygen therapy.

The patient underwent a high-resolution computerized tomography scan on day 3 which showed consolidation in the right upper lobe and left lower lobe.

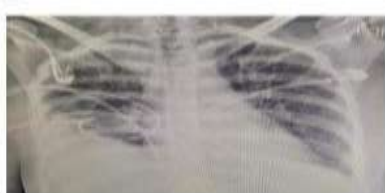Platelets improved to 1.2 lakhs by day 4 with a total leukocyte count of 4868.



CASE 4

A 23 years old patient presented to the emergency with a history of high-grade continuous fever, associated with chills and rigors for a week. The patient had a history of shortness of breath grade 2 mMRC for two days associated with chest pain which aggravated on deep inspiration, not associated with wheezing. The patient had a history of cough, not associated with sputum or hemoptysis.

Complete blood count showed decreased total leucocyte count of 3267 with a platelet count of 24000 on day 1. Chest x-ray showed bilateral pleural effusion right greater than left.



The patient was positive for dengue NS1 antigen. The patient was managed with antibiotics, analgesics, antipyretics IV fluids, single donor platelet and oxygen therapy. By day 5, the patient was afebrile, maintained normal saturation in room air with a total leucocyte count of 4923 and 84000 platelet count.

CASE 5

Patient, 28 years old, presented with a history of high-grade fever for four days, associated with chills and rigors with complaints of cough, scanty, mucoid sputum, shortness of breath grade 2 mMRC, wheezing, pain in the left side of the chest, catchy in nature, severe myalgia with to the outpatient department.

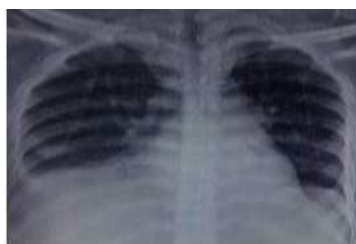
The patient did not have any co-morbidities, no history of ATT intake.

At the time of presentation, she was tachypneic and tachycardic with a saturation of 86 percent with room air which improved to 94 percent with oxygen therapy.

On examination vocal fremitus was reduced on the right infrascapular area, stony dull note was elicited in the right infrascapular area with absent breath sounds on the right infrascapular area.

No history of other co-morbidities, no history of ATT intake.

No history of smoking, biomass exposure, environmental exposure. On examination, the



patient was tachycardic with 102 degrees F temperature, saturation was 97 percent with room air.

Bilateral polyphonic wheeze was present throughout the lung fields on auscultation.

The patient was investigated with complete blood count, chest x-ray, sputum gram stain, culture sensitivity, fever work upon outpatient department basis.

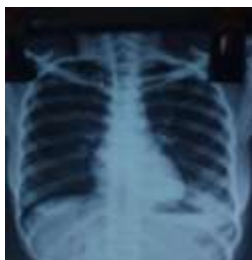Chest x-ray showed a left lower zone patch which was suggestive of pneumonia. The patient's total leucocyte count was 3465 and platelet count was 1.2 lakhs.

The patient was positive for dengue IgM antibodies. Sputum gram stain showed gram-positive cocci.

The patient was put on antibiotics, analgesics, and

antipyretics for seven days. The patient was reviewed in the outpatient department with a repeat

chest x-ray and CBC count showing resolution.



II. DISCUSSION

The clinical course of dengue has three phases: febrile phase, critical phase or leakage phase, and convalescence phase. Plasma leakage starts at the end of the febrile phase. The febrile phase lasts for 2-7 days whereas the critical phase lasts for 24-48 hours. Pleural effusion and ascites are seen in the leakage phase [2]. Milder forms resolve spontaneously whereas massive leakage needs diuretic therapy [2]. In our series, we used diuretics in case 2 as the patient was having massive pleural effusion whereas in case 4 the effusion resolved spontaneously. A study conducted by Rosana Souza Rodrigues, et al had pleural effusion the most common CT finding [4]. Endothelial dysfunction in dengue fever which causes third space loss is attributed to cytokines such as tumor necrosis factor, NS1 antigenemia, lipid mediators like platelet-activating factor, and leukotrienes [5]. There is no literature about a pneumothorax in dengue fever. Case 1 was managed simultaneously for pneumothorax and dengue. The patient was given hemostatics prophylactically in view of decreased platelet counts. The interrelationship between dengue and pneumonia has been sporadically reported in the medical literature.

Pneumonia can also, be a complication in dengue fever [6]. In our series, case 1, case 3, and case 5 had consolidations radiologically which was suggestive of pneumonia. There is no specific drug treatment for dengue fever, antibiotics have no benefit in controlling the infection, treatment aims to reduce the symptoms [7]. In our series, antibiotics were started in view of leukopenia and consolidations in radiology.

CONCLUSION

Pulmonary manifestations are not common in dengue fever. Findings in radiology suggest about vascular permeability. Dengue can be considered in the differential diagnosis of patients with fever, diffuse pulmonary infiltrations, pleural effusions. Recognition of the findings helps

early initiation of the treatment and prevents mortality.

REFERENCES

- [1]. Edson Marchiori, Bruno Hochhegger, Glaucia Zanetti. Pulmonary manifestations of dengue. *J Bras Pneumol.* 2020;46(1): e20190246
- [2]. Siripen Kalyanarooj. Clinical Manifestations and Management of Dengue/DHF/DSS. *Tropical Medicine and Health.* 2011;39(4): 83-87
- [3]. Swapndeeep Singh Atwal, Swapnil Puranik, Shibani Mehra, Umesh Chandra Garga. Pneumocystis Pneumonia-A Novel Complication in a Non-HIV Dengue Patient. *Journal of Clinical and Diagnostic Research.* 2014;8(9): 01-02
- [4]. Rosana Souza Rodrigues, Ana Livia Garcia Brum, Marciano Viana Paes, et al.
- [5]. Lung in Dengue: Computed Tomography Findings. *PLOS ONE.* 2014;9(5): e96313
- [6]. Gathsaurie Neelika Malavige, Graham S. Ogg. Pathogenesis of vascular leak in dengue virus infection. *Immunology.* 2017;151: 261-269
- [7]. Viroj Wiwanitkit. Dengue Pneumonia: A Tropical Problem. *International Journal of Pulmonology and Infectious Diseases.* 2018
- [8]. Dengue fever-symptoms, treatment, prevention. southern cross.co.nz. Last Reviewed-March 2020